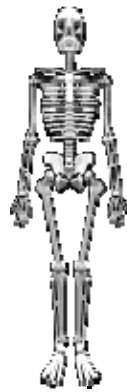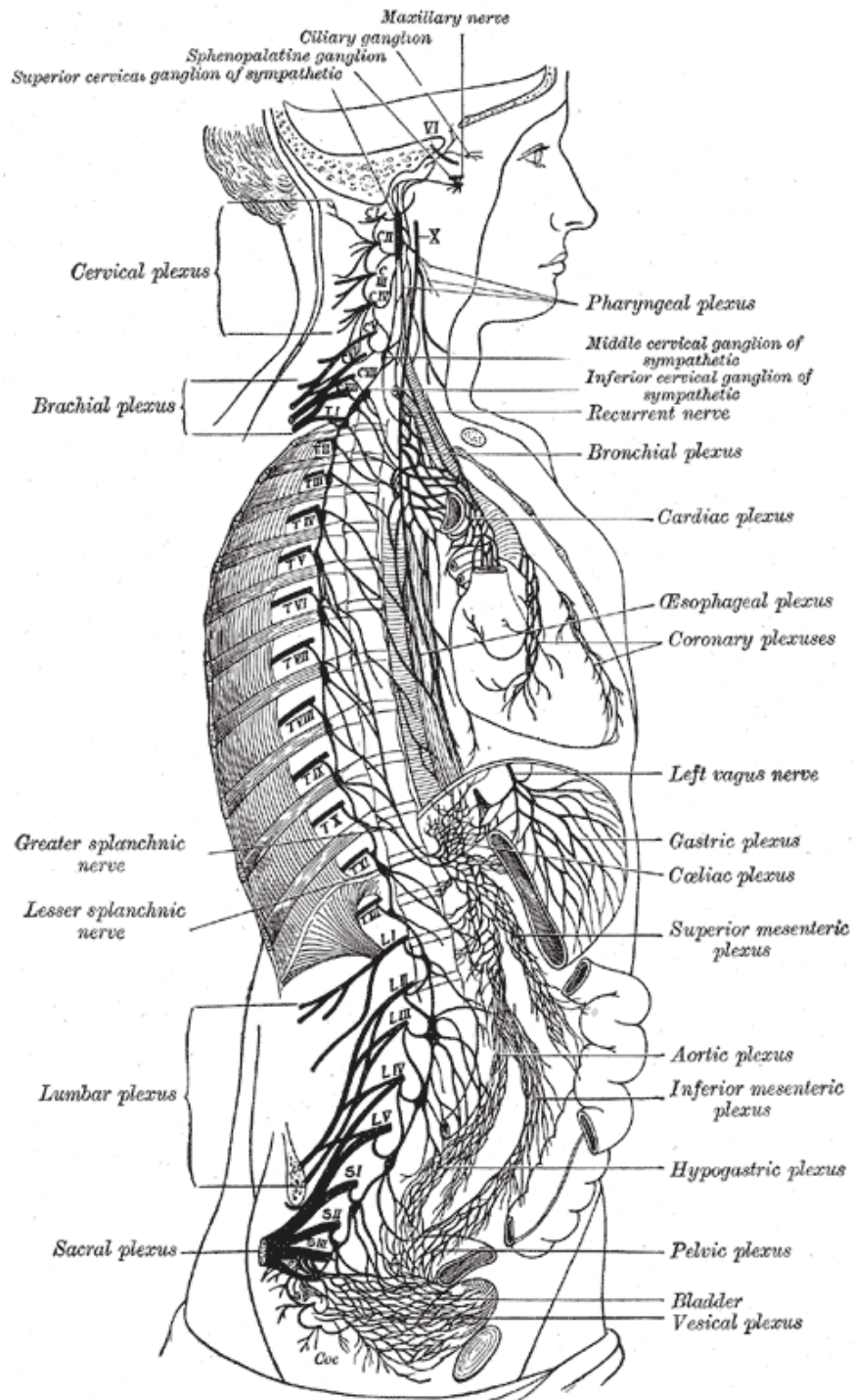


# **ANATOMY SKETCHES**





## **The Sympathetic Nerves**

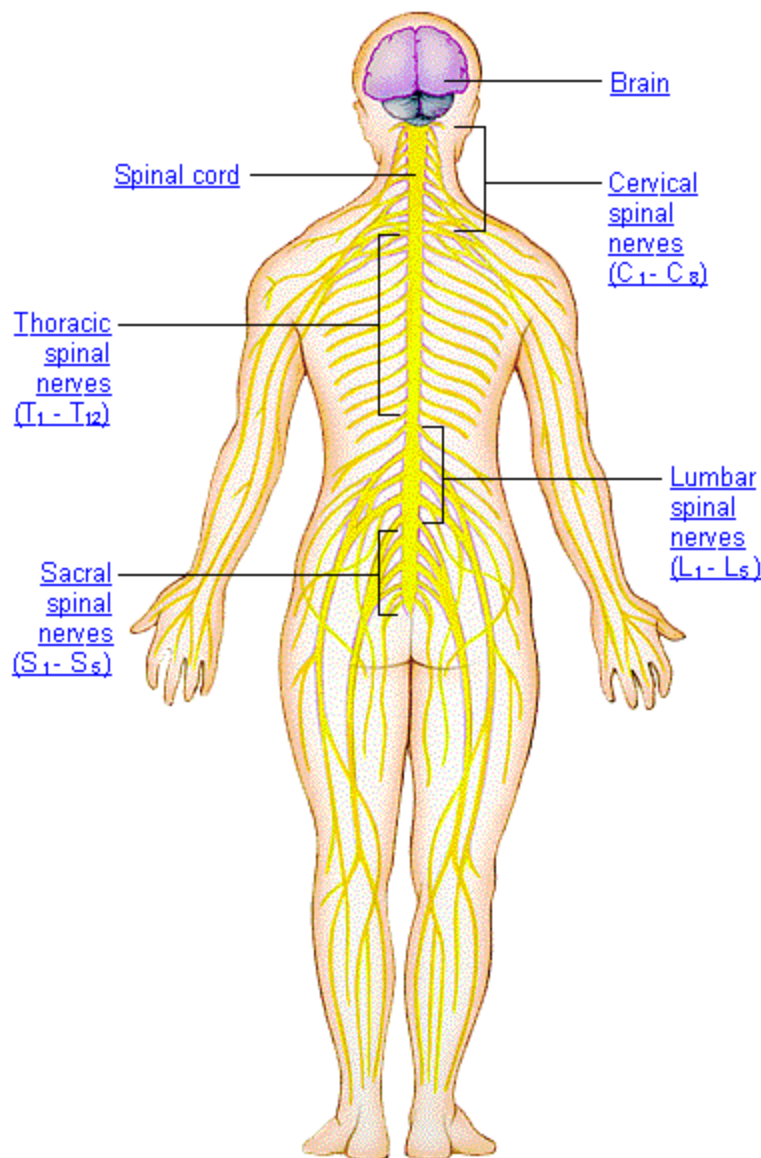
Henry Gray (1825–1861). *Anatomy of the Human Body*. 1918

The **sympathetic nervous system** innervates all the smooth muscles and the various glands of the body, and the striated muscle of the heart. The efferent sympathetic fibers which leave the central nervous system in connection with certain of the cranial and spinal nerves all end in sympathetic ganglia and are known as **preganglionic fibers**. From these ganglia postganglionic fibers arise and conduct impulses to the different organs. In addition, afferent or sensory fibers connect many of these structures with the central nervous system.

The right sympathetic chain and its connections with the thoracic, abdominal, and pelvic plexuses. (After Schwalbe.)

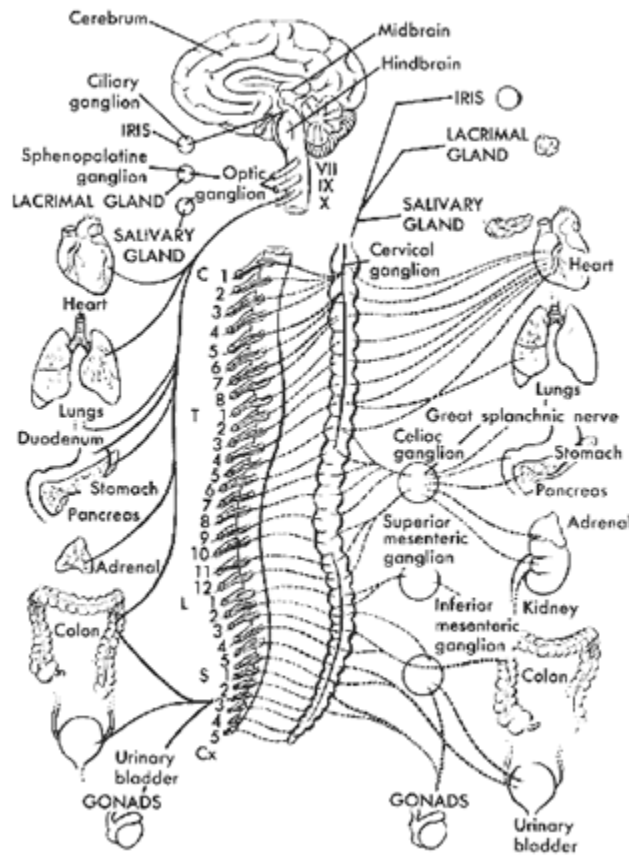
**Anatomy Sketch Source:** <http://www.bartleby.com/107/214.html>

## The Nervous System - Groups of Nerves

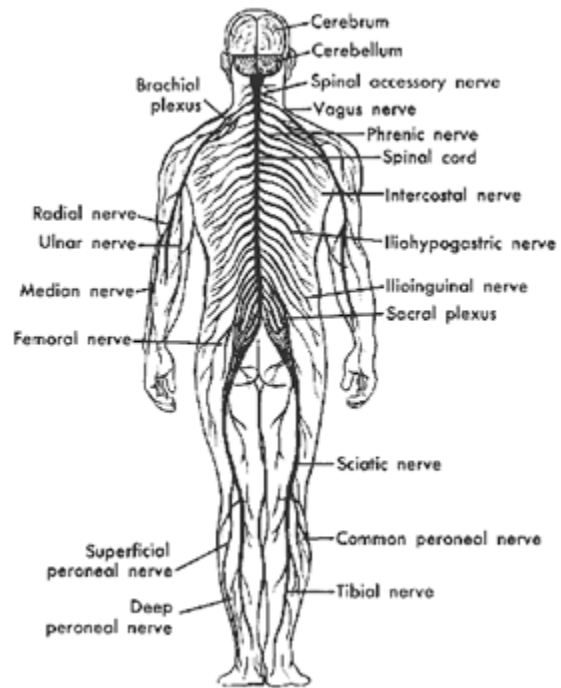


Your nervous system is composed of the central nervous system, the cranial nerves, and the peripheral nerves. The brain and spinal cord together form the central nervous system. The cranial nerves connect the brain to the head. The four groups of nerves that branch from the cervical, thoracic, lumbar, and sacral regions of the spinal cord are called the peripheral nerves. **Anatomy Sketch Source:** [http://www.ama-assn.org/insight/gen\\_hlth/atlas/atlas.htm](http://www.ama-assn.org/insight/gen_hlth/atlas/atlas.htm)

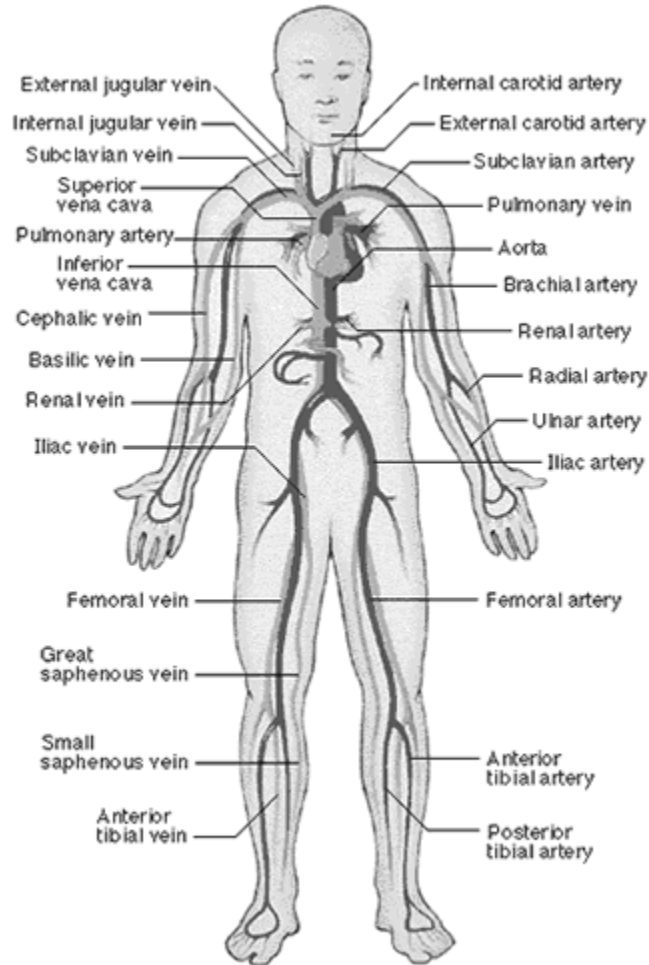
## The Human Parasympathetic Nervous System



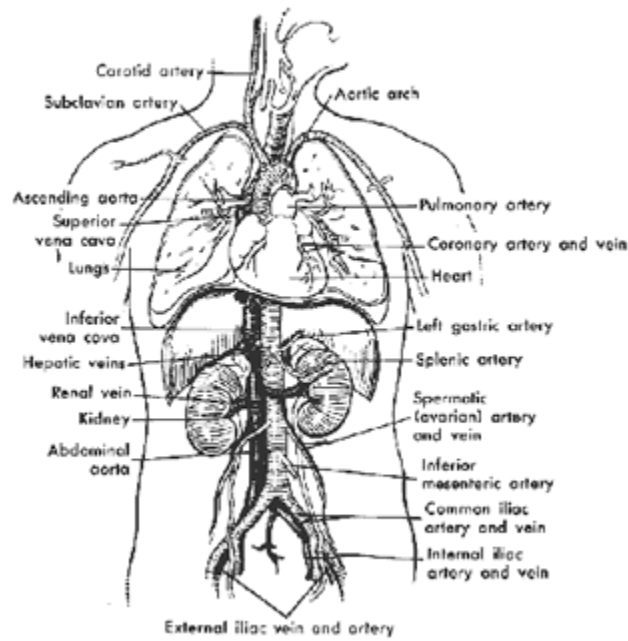
# Peripheral Nervous System



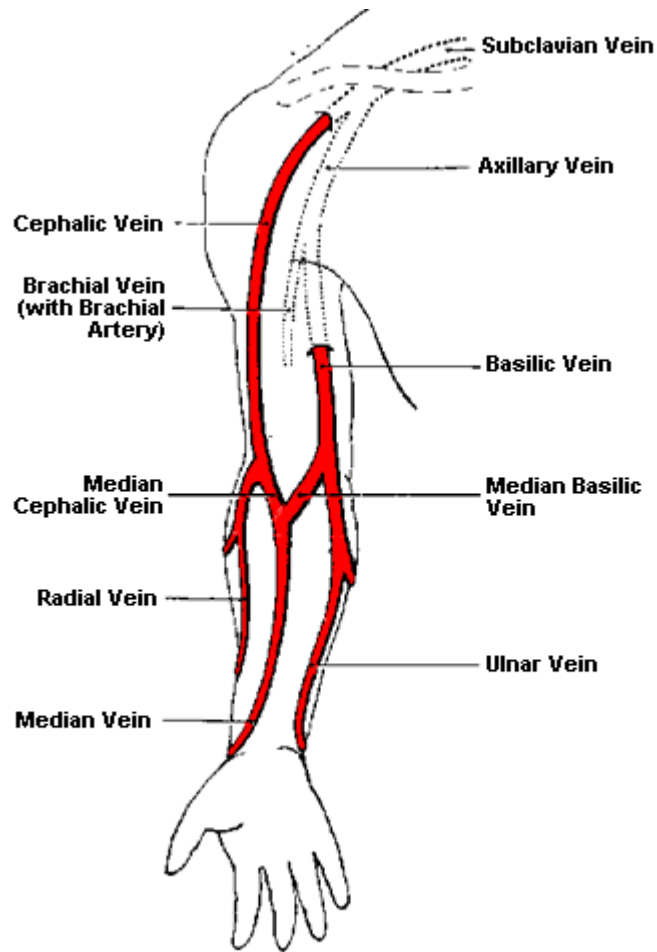
## The Circulatory System



## Arteries & Veins of the Mid and Upper Body



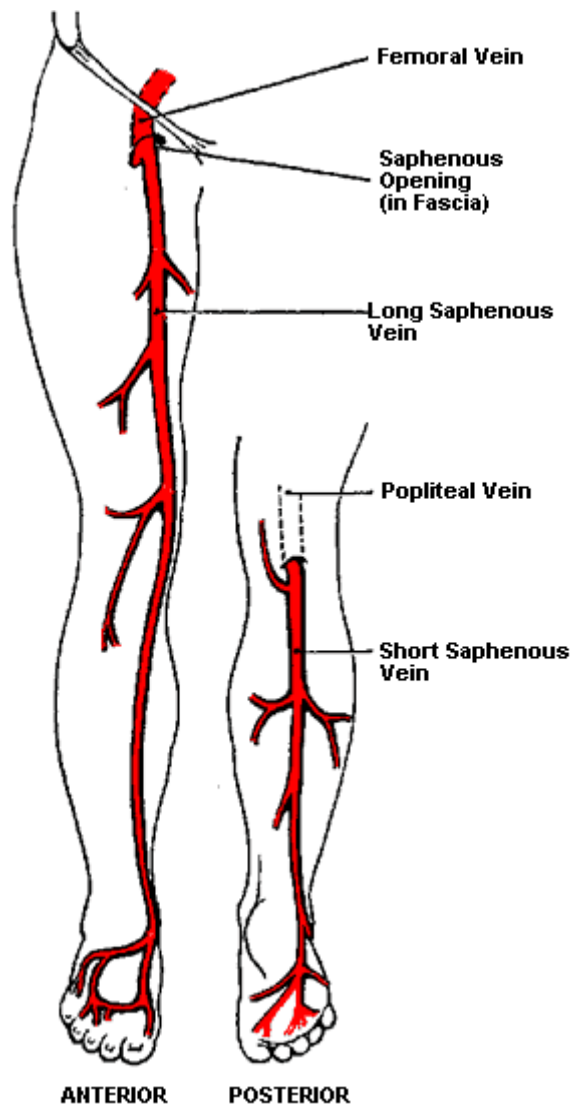
## Veins of the Right Arm



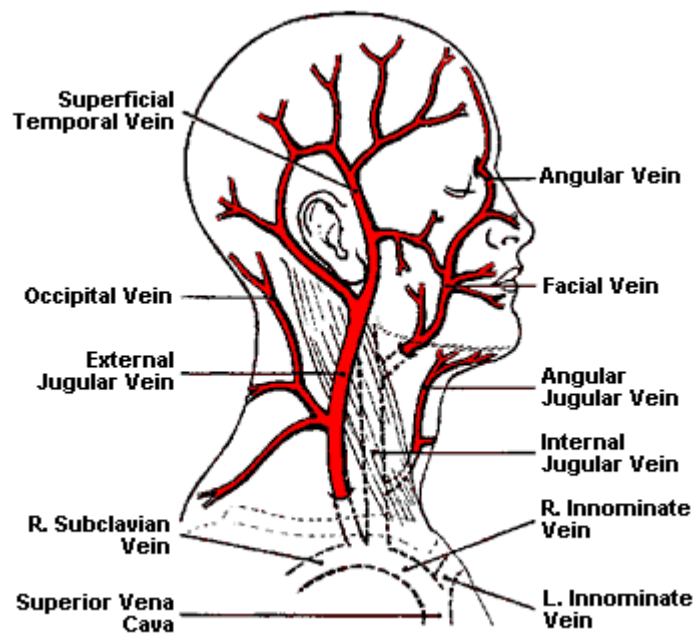
Superficial veins of the right upper limb



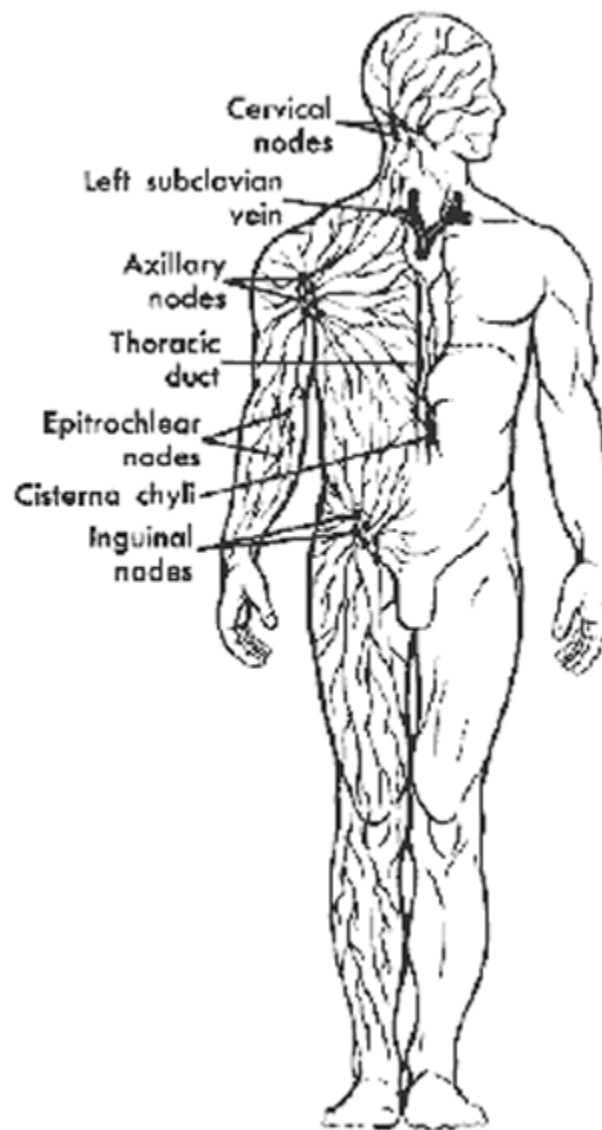
## Veins of the Anterior & Posterior Leg



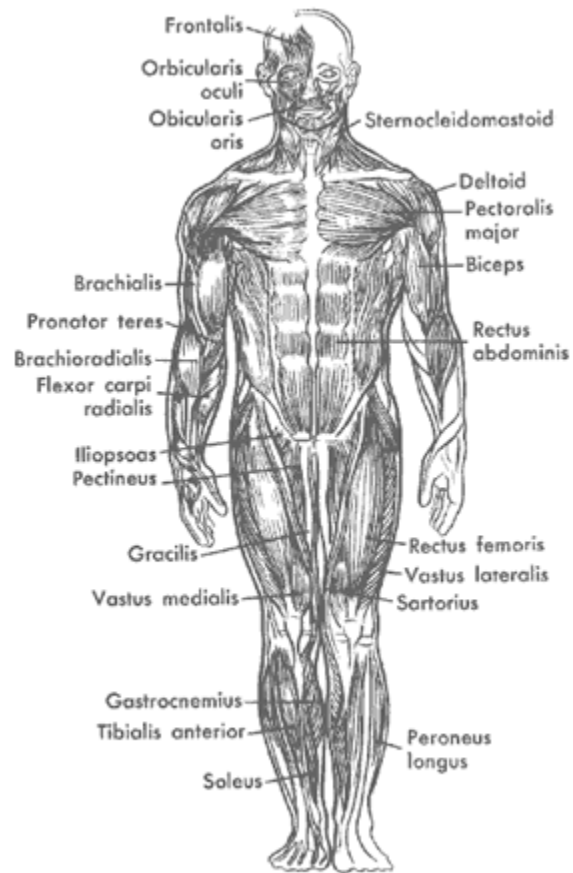
## Veins of the Head & Neck



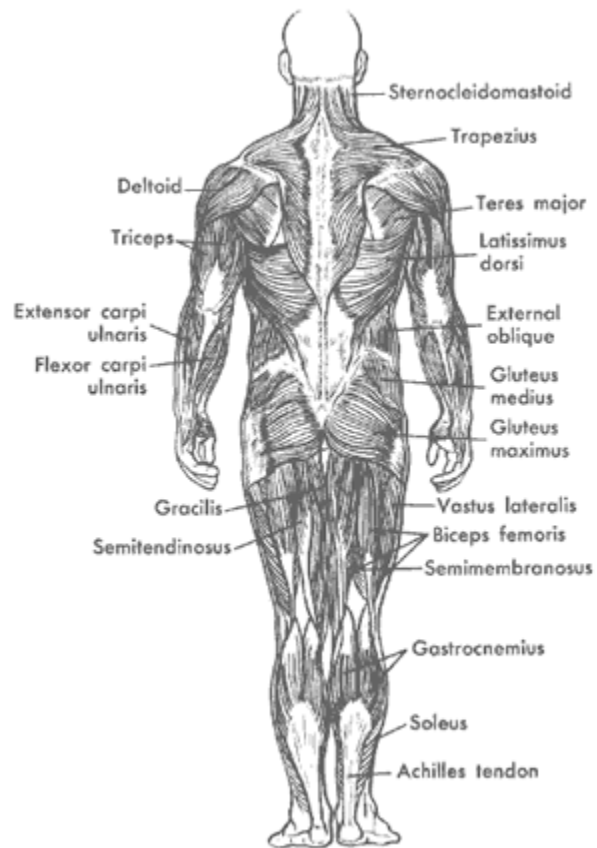
## The Human Lymphatic System



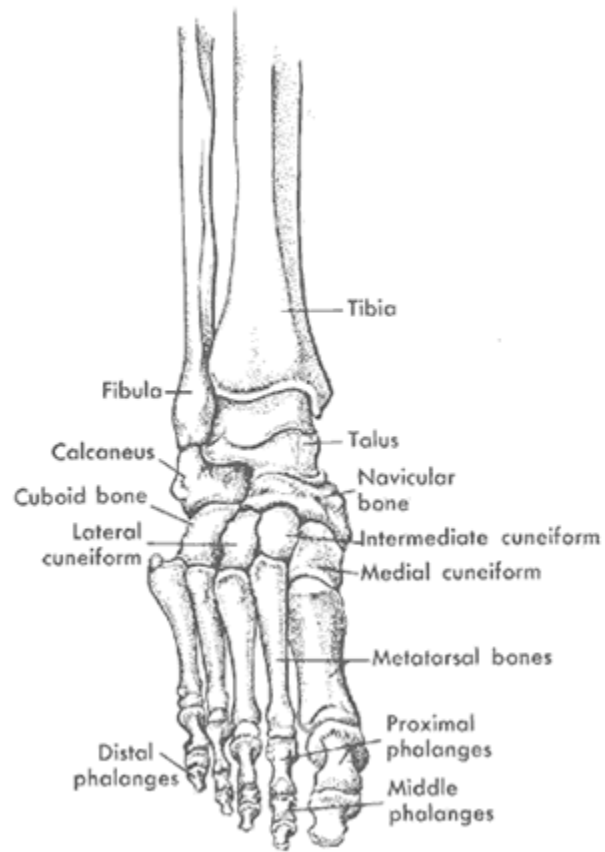
## The Main Anterior Muscles of the Human Body



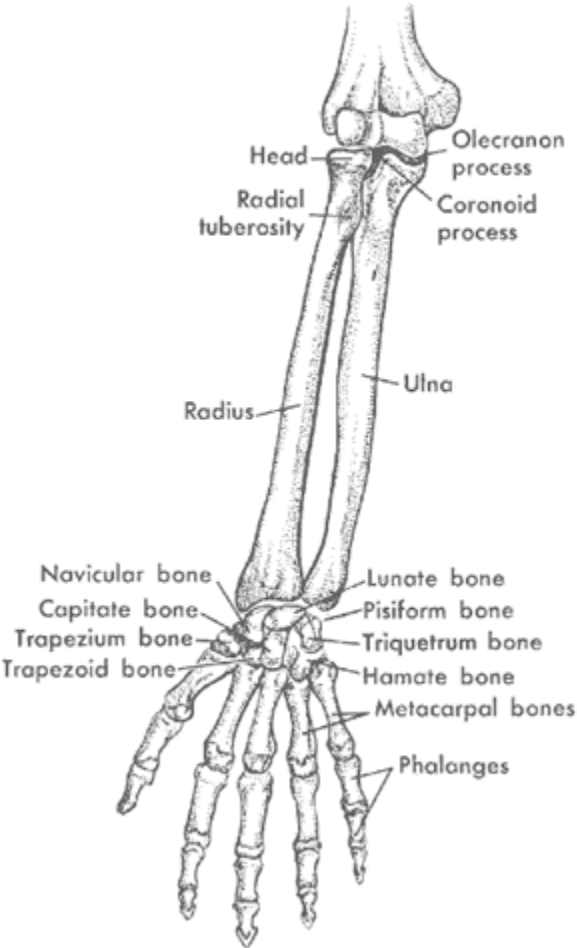
## The Main Posterior Muscles of the Human Body



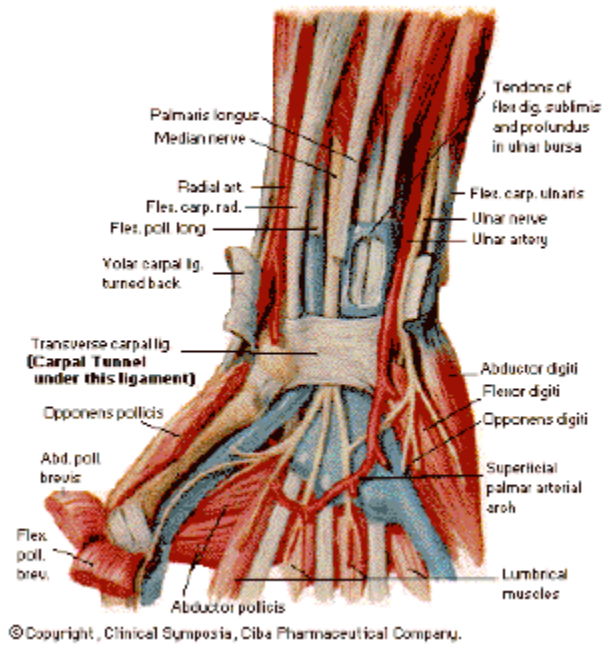
## The Ankle



**Features of the Forearm & Hand**

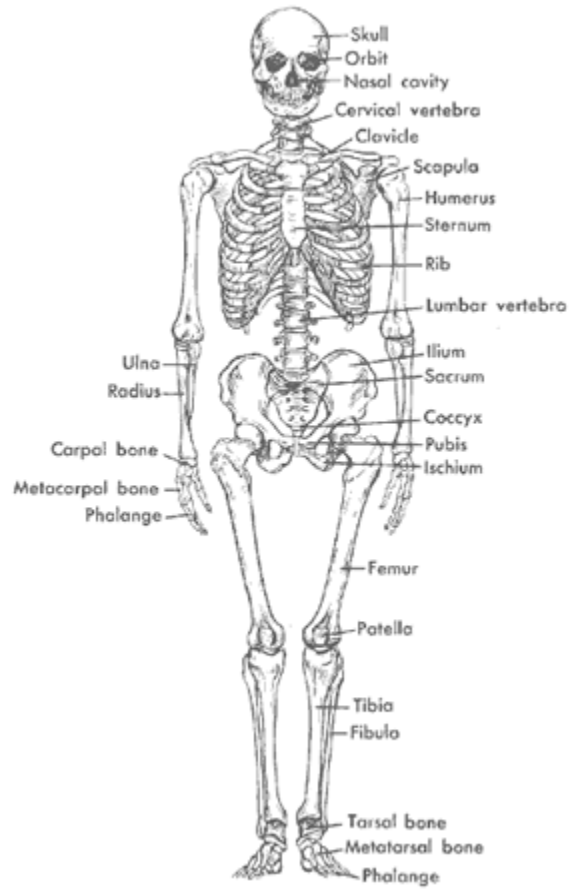


# Wrist

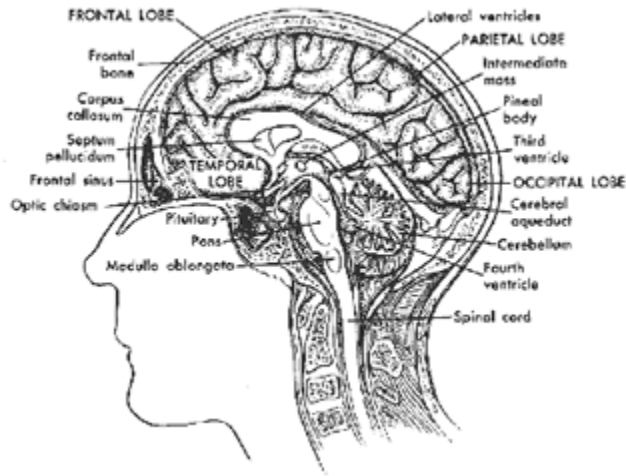




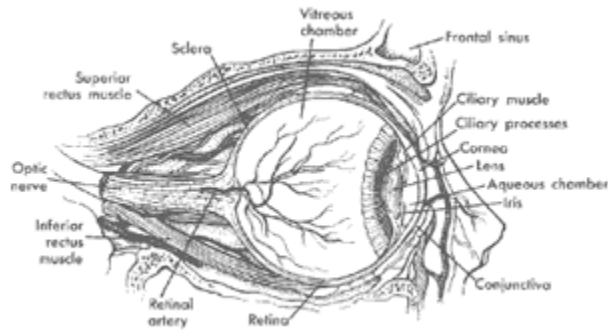
# The Human Skeleton



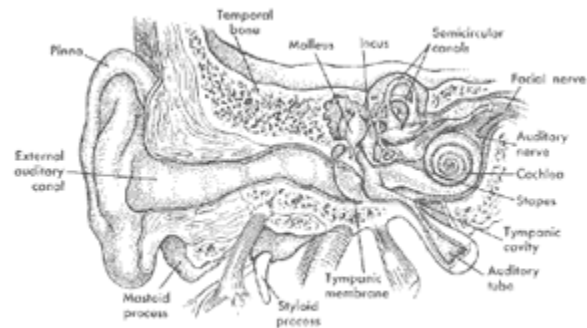
## The Human Brain



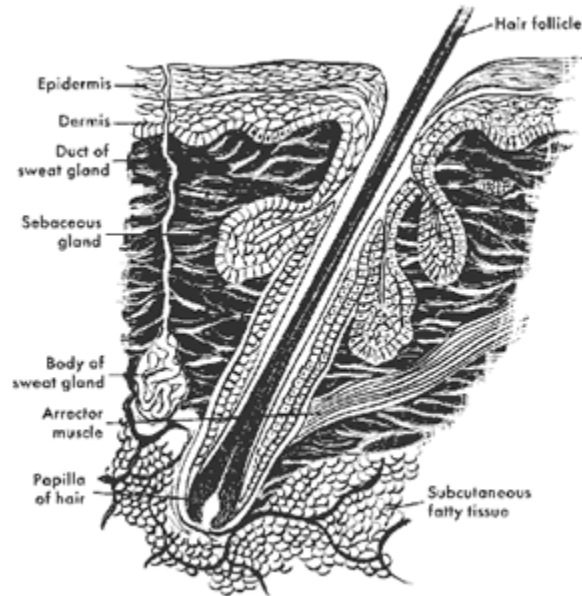
## The Human Eye



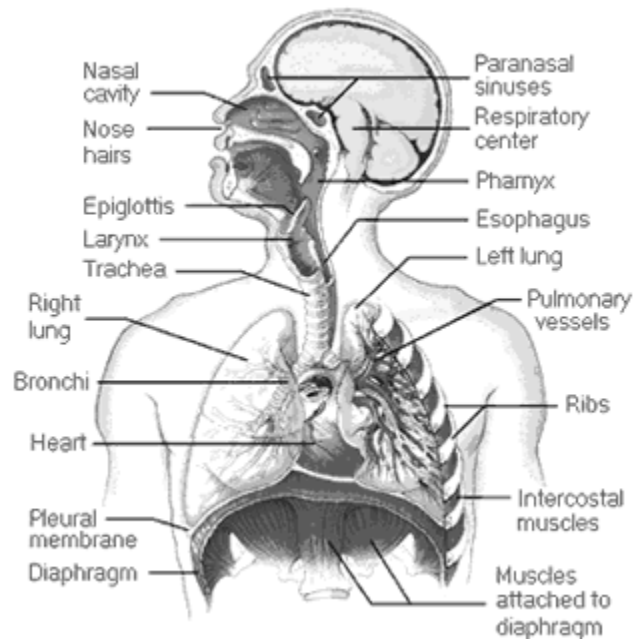
## The Human Ear



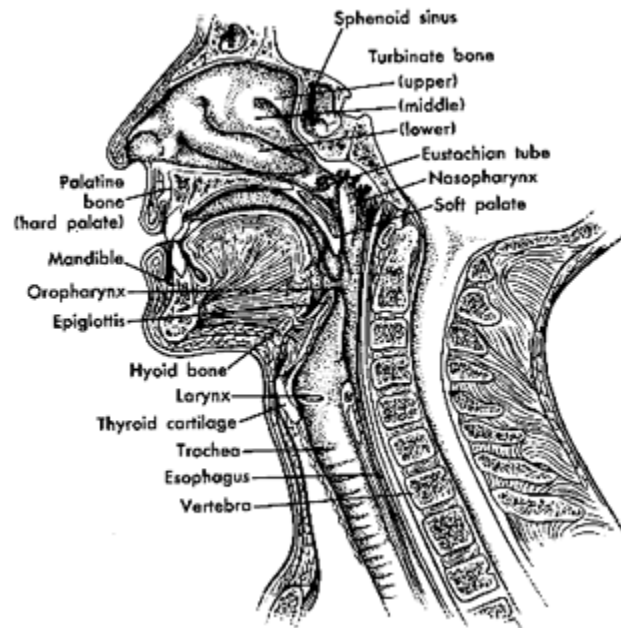
## Cross-Section of the Human Skin



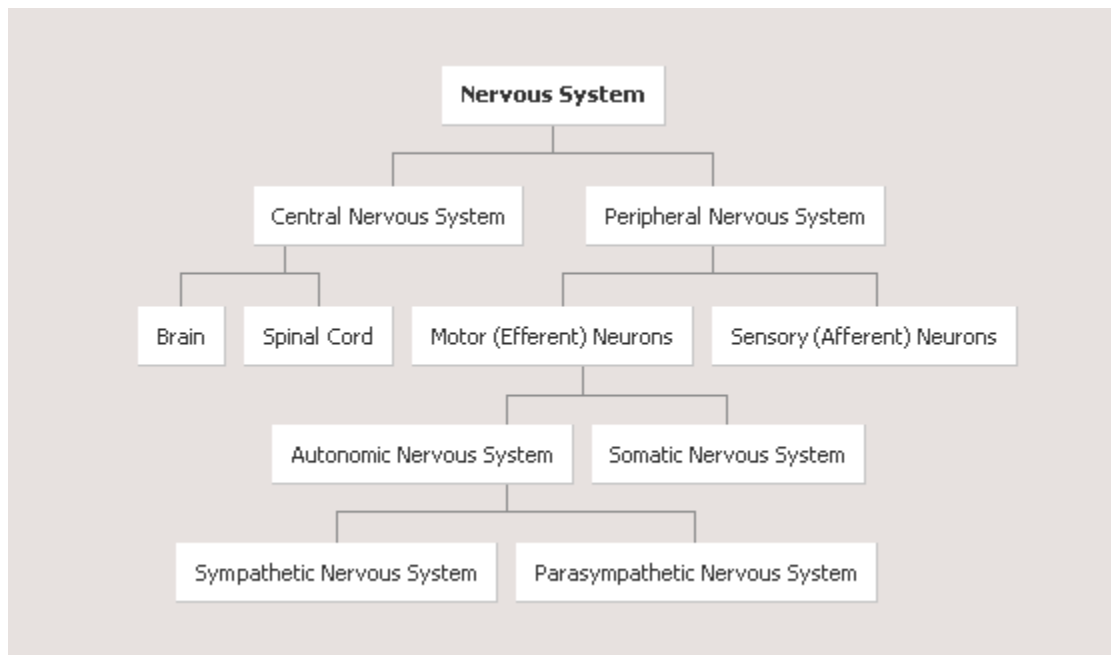
## Respiratory System



## Upper Respiratory Tract

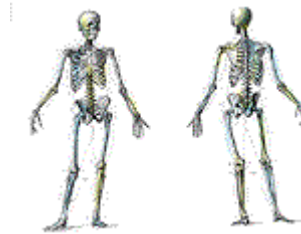

## Nervous System Organization



**Anatomy Sketches Source:**

**<http://www.medword.com/anatomy.html>**



**Also please visit Human Anatomy Online at:**

**<http://www.innerbody.com/htm/body.html>**